# Clinical Uses of In-Shoe Pressure Analysis in Podiatric Sports Medicine

**Bruce E. Williams, DPM***
**James D. Yakel, DPM†**

Athletic injuries of the foot and lower extremity are commonly treated with custom foot orthoses. These devices usually provide immediate relief of the athlete's pain and dysfunction. Occasionally, however, they do not help, or even increase the patient's discomfort. We discuss a method of using in-shoe pressure-measurement systems to analyze the athletic patient's foot and lower-extremity function before and after treatment with custom foot orthoses, with a focus on sagittal plane biomechanics. Case histories are presented of athletes whose gait pathologies were identified and treated successfully using an in-shoe pressure-measurement system. (J Am Podiatr Med Assoc 97(1): 49-58, 2007)

As seen during the 2004 Summer Olympic Games in Athens, Greece, athletic performance is scrutinized from every conceivable angle by judges, officials, the media, and the public. Athletes who want to improve their performance and alleviate any chronic problems that may adversely affect their performance may benefit from the use of high-technology measuring devices that are common in sports clinics. An athlete's gait is a critical component of sports and injury. Human gait is a complex action that has received extensive study, with various methods used to detect musculoskeletal abnormalities. Given the high prevalence of lower-extremity musculoskeletal pain in athletes, it was inevitable that athletes and their coaches and trainers would use gait analysis to examine the athletes' overall gait patterns and to correct any identified inconsistencies or asymmetries.

There are two fundamental forms of gait analysis: observational and computerized. Observational gait analysis is the more widely used because of its simplicity and cost-effectiveness. However, observational gait analysis is extremely subjective and has been shown to be unreliable because the eye cannot detect certain locomotor events that occur in less than $1/12$ of a second.[1, 2] With the advancement of technology, computerized gait analysis has progressed from still photography[3] to film, to videotape, and now to computers and high-speed/high-resolution digital cameras with kinematic capturing capabilities. Electromyograms, force plates, and in-shoe pressure-measurement systems are regularly used in gait analysis as well.

The advent of in-shoe pressure-measurement systems has offered a different view of what actually happens in an athlete's or patient's shoes during gait. In the past, podiatric physicians had to rely on data supplied primarily by force plates that patients walked over while barefoot to view actual foot function. This method offered little insight into what happened in certain types of athletic shoes or with certain foot types during actual function in sports.

Initially, in-shoe pressure-measurement systems were used to evaluate and treat patients with diabetic foot ulcers.[4, 5] The role of in-shoe pressure-measurement systems has expanded to treatment of patients with not only foot pathology but also acute and chronic postural complaints higher in the kinetic chain of gait function.[6, 7] The use of in-shoe pressure-measurement systems such as the F-Scan (Tekscan, Boston, Massachusetts) and Pedar (Novel Inc, Munich, Germany) allows physicians to determine what the foot is doing in the shoe and then to identify certain functional asymmetries that may lead to gait-related pathologies. The dynamic information provided by the pressure mapping during foot function can be used to create a custom foot orthosis to improve the patient's outcomes in a more objective manner.

Athletes may benefit greatly from in-shoe pressure

*Private practice, Merrillville, IN.
†Private practice, Longmont, CO.
*Corresponding author:* Bruce E. Williams, DPM, 8120 Georgia St, Ste A, Merrillville, IN 46410.

analysis because of the variety of foot, ankle, and other musculoskeletal complaints that may be caused by asymmetrical gait patterns. There is a need to describe a uniform process by which in-shoe pressure-measurement systems can be used to evaluate orthotic outcomes in athletic patients. We describe a simple format aimed at increasing overall symmetry of lower-extremity function in order to improve outcomes of foot-orthotic treatment in the athlete.

## Sagittal Plane Biomechanics

Most in-shoe pressure-measurement systems allow the representation of force movements by force-time curves. These curves are an excellent way of representing the entire gait cycle, from initial double-limb support to single-limb support and, finally, terminal double-limb support (Fig. 1). Each of these phases is easily identified using the in-shoe pressure-measurement system while watching the pressure recordings or using the force-time curves. Any inconsistency in function from one foot strike to the next can easily be identified and correlated to the period of its origination.

In the foot, sagittal plane progression may be blocked at the ankle joint, the calcaneus, or the first metatarsophalangeal joint.[8] The range of motion in the sagittal plane of the foot and lower extremity is approximately five times greater than the range of motion in either the frontal or transverse plane of function.[9, 10] Therefore, a fundamental understanding of sagittal plane biomechanics is essential when using in-shoe pressure analysis. Although its full description is beyond the scope of this article, we note the relevant information in interpretation of normal and abnormal sagittal plane biomechanics.

**Figure 1.** An entire single-limb strike of the gait cycle. The red area represents initial double-limb support and the contact phase of single-limb support; the blue and pink areas, the midstance and active propulsion phases, respectively, of single-limb support; and the green area, terminal double-limb support and the toe-off phase of single-limb support.

As the foot strikes the ground at contact (red area in Fig. 1), the calcaneus must be allowed to roll freely forward for normal progression. This is rarely a stopping point during sagittal plane mechanics, but trauma to the calcaneus can create a serious delay in the process of forward momentum of the foot during and after heel contact.

The second phase in sagittal plane progression is when the foot is fully loaded on the ground and moves from the contact phase to midstance (blue area in Fig. 1). At this point, only one limb is fully supporting the weight of the body as it continues to move forward. It is important at this stage that the foot be allowed to dorsiflex at the ankle joint. In other words, the lower leg must rotate freely forward over the foot to approximately 10°. If there is any limitation, functional or structural, of ankle joint range of motion at this stage, the foot will be forced to either lift the heel from the ground early (ankle joint equinus) or collapse at the midtarsal joint to make up for any lost dorsiflexion at the ankle joint. Both compensations are usually seen in patients in their contralateral limbs—ie, ankle joint equinus in one limb and midtarsal joint collapse in the other limb. Often one foot will pronate more or longer than the other foot, with subsequent subtalar joint pronation and midtarsal joint collapse, and the contralateral limb will then effectively remain more stable at the subtalar and midtarsal joints and be prone to an equinus compensation at the ankle joint. This is a very subtle effect and can be difficult or impossible to see without the use of the F-Scan system or a high-speed video-analysis system.

The second part of single-limb support is active propulsion (pink area in Fig. 1). In this phase, as the heel lifts from the ground, the metatarsophalangeal joints must extend. When motion in the first metatarsophalangeal joint is limited, either structurally or functionally, the entire postural chain can be affected. Hall and Nester[11] demonstrated that by reducing dorsiflexion at the first metatarsophalangeal joint, proximal joint kinematics were influenced. Dananberg[6, 7, 12] was one of the first researchers to report the effects of what he termed *functional hallux limitus*, which is described as the inability of the hallux to dorsiflex during the single-limb stance phase of gait. Clinical evaluation consists of moderately loading the first metatarsal head while attempting to dorsiflex the hallux, leading to a limitation of hallux dorsiflexion. Approximately 20° to 25° of hallux dorsiflexion should be available.[12] Failure to achieve this amount of motion indicates functional hallux limitus.

The final phase of stance is toe-off (green area in Fig. 1). This is represented by the final curve in the

force-time curve segment as it diminishes toward terminal double-limb support.

During midstance and into active propulsion, normal progression should be reflected by ankle dorsiflexion, knee joint and hip extension, and an increase in lordosis. When sagittal plane blockade is present, a flexion compensation occurs all the way up the lower kinetic chain. The ankle and knee now flex, and the spine becomes straight. In two different studies in 1990 and 1999 that addressed sagittal plane blockage, DiNapoli et al[13] and Dananberg and Guiliano,[14] respectively, demonstrated improvements with use of orthotic devices in a variety of pathologic conditions, such as sciatica, sacroiliac dysfunction, spinal stenosis, nonspecific chronic low-back pain, temporomandibular joint and neck pain, hip pain, knee and leg pain, and traumatic injuries. It is clear that the combination of in-shoe pressure analysis and knowledge of sagittal plane biomechanics greatly expands the realm of treatment of sports medicine injuries with custom foot orthoses.

## Methods of Interpreting In-Shoe Pressure Data

Once the need for unfettered sagittal plane motion is understood, the data that the in-shoe pressure-measurement systems can provide can begin to be appreciated. In-shoe pressure-measurement systems measure vertical forces. Pressure-mapping devices show high and low pressures or "hot spots," but they also offer many other useful data.[15] For example, changes in the center of pressure as it moves from the heel to the toes—and whether it has a more medial, midline, or lateral progression—can help predict foot function.[16-18]

At the end of a description of transmission of forces through the kinematic foot, Root et al[9] comment briefly on what they consider to be a normal progression of plantar pressures. They essentially state that the center-of-force icon progression line should start medially at the heel at contact until the early midstance phase, then progress to the midline of the foot from early until late midstance, and then finally progress to the medial aspect of the foot at or between the first and second metatarsal heads by heel lift and then through the hallux at toe-off.

The F-Scan system allows the user to watch both feet side by side, statically or in function from stride to stride, as if the patient were "bunny hopping" through the gait cycle. This synchronized approach can be more effective than trying to make observations from one right footstep and then one left footstep.

The F-Scan system allows for comparison of many different parameters, such as the center-of-force icon and trajectory, accelerations of each foot, early loss of or prolongation of pressures, and abnormally high or low areas of pressure in certain areas of the feet. For example, when evaluating for a short limb, it is common to see an early loss of heel pressure in one limb coupled with a much faster acceleration of the center-of-force icon in the same foot.

Evaluation of the center-of-force trajectory and an increase or decrease in medial arch pressures may help identify an overly pronated or supinated foot or avoidance of a joint that may be functionally or structurally blocked in gait. High metatarsal pressures could indicate metatarsalgia or neuroma, and an absence of pressure beneath the first metatarsophalangeal joint, with or without high hallux pressures, often indicates functional hallux limitus (Fig. 2). F-Scan recordings offer large amounts of visual information useful in identifying asymmetries that may indicate functional pathology.

The ability to assess and compare force-time curves is another important tool offered by in-shoe pressure-measurement systems. During gait, vertical forces are highest under the heel and forefoot. As the body, or center of gravity, moves over these parts, this is reflected as peaks in force-time curves. A typical force-time curve would appear as a double hump, with peaks as the load increases and valleys as the load

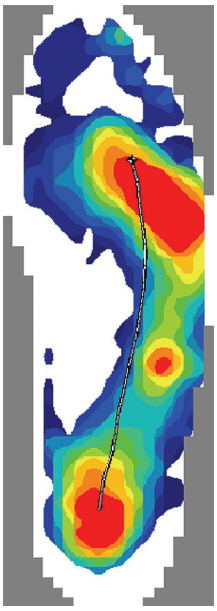

**Figure 2.** An excellent representation of functional hallux limitus. Note the lateral deviation of the center of pressure and the absence of pressures beneath the first metatarsophalangeal joint.

decreases. The first peak corresponds to heel contact, and the second peak is contact of the ball of the foot or toe-off (Fig. 1). The trough or valley between these peaks represents an upward movement in the center of gravity as the pelvis ascends to allow the swing limb to clear the ground, opposing gravity's pull on the body.[19] This trough also corresponds with the single-limb support phases of midstance and active propulsion.

With abnormal gait patterns, a flat area in the curve can be either a stoppage of force (less likely) or a stoppage of movement (more likely) (Fig. 3). Problem areas can be identified specifically in the heel, forefoot, or entire foot just by analyzing the specific phase of gait in which the curve flattens. Ankle joint range of motion, functional hallux limitus, and midtarsal joint collapse can cause flattening of the curves, suggesting a lack of propulsion during prolonged force. With a properly functioning orthotic device or orthotic modification, a more symmetrical and nonflattened progression is often seen throughout the gait cycle. Comparing and contrasting these curves from right to left and from test to test allows the physician to track improvements or detriments in any modifications made to custom foot orthoses.

The ability to objectively compare and record all of these factors allows the formation of a strong predictive pattern regarding the patient's function. Over time, improvements in symmetry will lead to improvements in pathologic entities involving the foot, lower leg, upper leg, and gait and posture.

## Materials

The F-Scan in-shoe pressure-measurement system was used for all case studies reported here. The F-Scan system consists of a 9-V battery–operated transducer unit, a 9.25-m-long coaxial cable, gait-analysis software, and an IBM-compatible computer. A 7-μm flexible pressure-sensitive insole with 960 sensing elements per foot and a spatial resolution of 4 sensors per square centimeter, or 25 sensors per inch, was placed into each shoe. All of the subjects were calibrated for weight. Patients were tested while wearing their normal footwear.

After initial testing, either prefabricated or heat-molded temporary inserts, or the patient's custom foot orthoses, were placed into the shoes, and modifications were made to the inserts until symmetrical or near-symmetrical gait patterns were achieved.

## Case Studies

### Case 1

A 17-year-old girl complained of severe right arch pain. She was participating in high school cross-country running when the arch began to hurt. She was considering quitting the team because of the pain, which had not responded to treatment. She had undergone physical therapy, taping, shoe changes, prefabricated inserts, rest, and ice application. None of these therapies provided any relief.

Clinically, there was moderate tenderness along the course of the plantar fascia of the right foot. Functional hallux limitus was present, and limb length was equal. No hypermobility of the first ray was noted, and ankle joint ranges of motion were normal, with no restriction. Low-Dye taping was applied to the right foot, with care taken to plantarflex the first metatarsal. When the patient returned 1 week later, she reported significant relief of her symptoms, and a computerized gait analysis was performed.

The results of the gait analysis showed that the center-of-force trajectory was lateral to the midline in the right foot (Fig. 4). Also evident was an absence of medial longitudinal arch pressure on the right foot. The force-time curves were poorly defined in this patient, and there was severe flattening of the midstance period curve in the right foot (Fig. 5).

A first-ray cutout was added to the right orthosis. This resulted in a midline center-of-pressure trajecto-

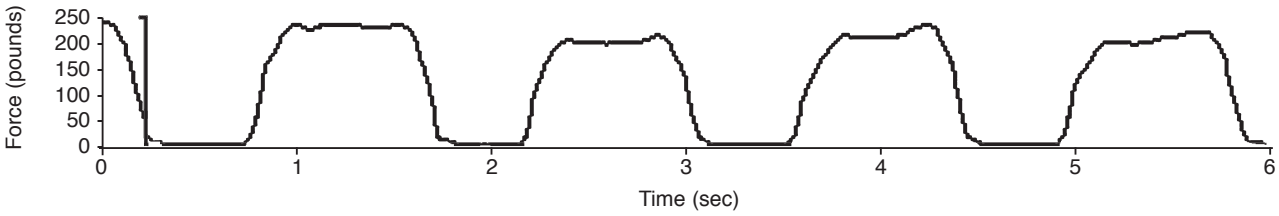


**Figure 3.** Force-time curve. Abnormal gait patterns cause the flat apex of the curve, representing a cessation of motion while the forces remain constant.

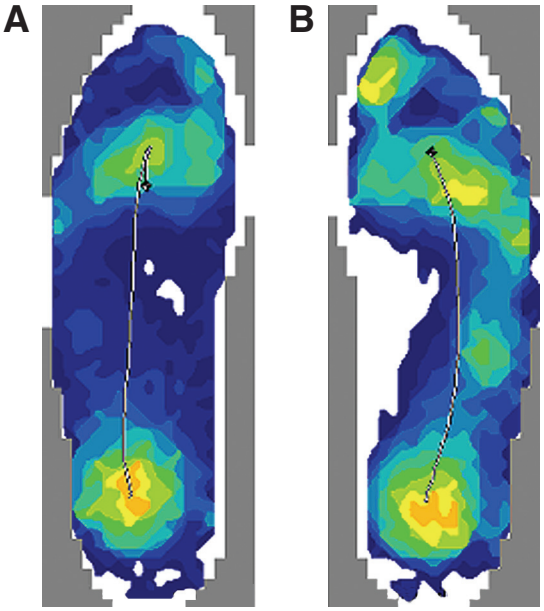


**Figure 4.** Case 1: Left (A) and right (B) in-shoe pressure recordings of a female cross-country runner before orthotic treatment.

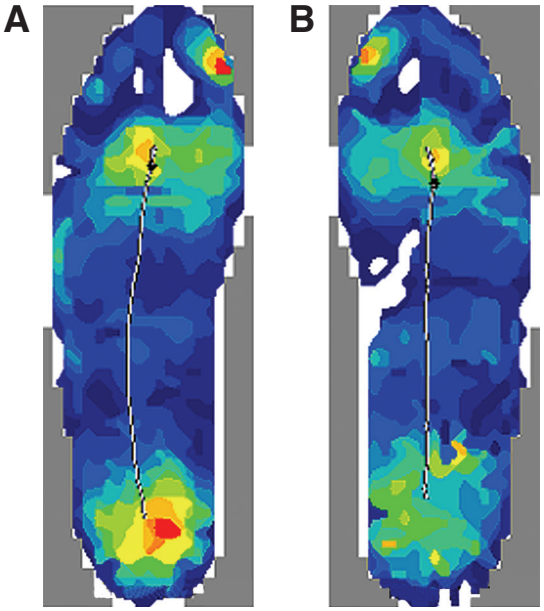


**Figure 6.** Case 1: Left (A) and right (B) in-shoe pressure recordings of a female cross-country runner after orthotic treatment.

ry bilaterally (Fig. 6) and more symmetrical force-time curves (Fig. 7). The patient resumed running within 3 days and competed in the state high school cross-country meet.

### Case 2

A 30-year-old male professional basketball player presented complaining of plantar fasciitis and Achilles tendinitis in the left foot. The left Achilles tendon was palpable and intact, with no deficit, no swelling, and pain on palpation. The patient had pain at the medial insertion of the left plantar fascia. He had functional hallux limitus and a hypermobile first ray bilaterally. He had marked ankle joint equinus bilaterally and a functional limb-length discrepancy, with the right limb shorter than the left, that disappeared when he assumed the neutral calcaneal stance position.

This patient presented with a pair of custom foot orthoses that he said controlled his chronic knee pain on the right but did not help his fasciitis or tendinitis. These devices were posted very high medially, but overall they fit poorly. He underwent casting for new custom foot orthoses, and because he liked a highly posted medial arch and heel, we added a 6° medial heel skive bilaterally and a ¼-inch heel lift on both devices to accommodate his bilateral ankle joint equinus.

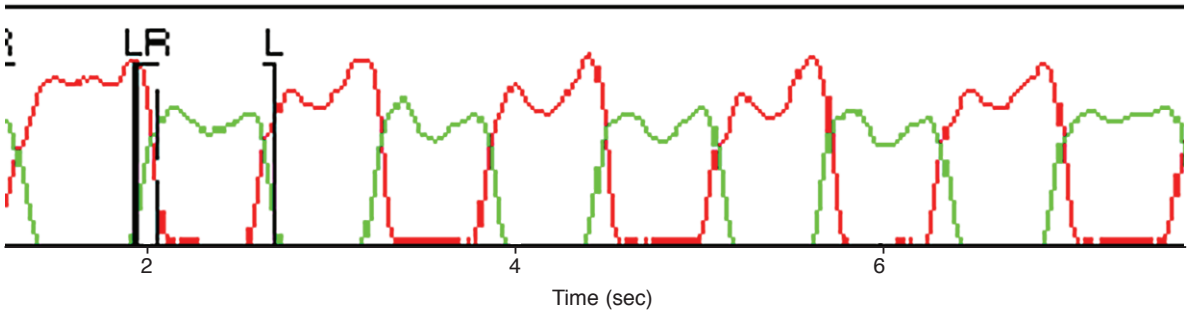


**Figure 5.** Case 1: Force-time curves of a female cross-country runner before orthotic treatment. Note the asymmetry of the left (red) and right (green) feet.

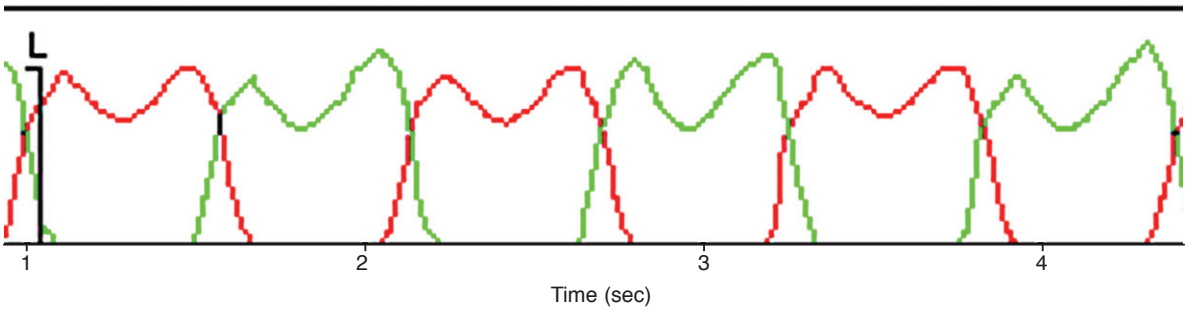


**Figure 7.** Case 1: Force-time curves of a female cross-country runner after orthotic treatment. Note the symmetry of the left (red) and right (green) feet.

The patient did not find these new orthoses to be comfortable, so he underwent F-Scan analysis and modification of the new devices. The patient's initial F-Scan static recordings showed a very erratic progression of his center-of-force trajectory and low pressures beneath the first metatarsophalangeal joints. His force-time curves were very asymmetrical, with an extremely rough pattern (Fig. 8).

After F-Scan testing, we added a kinetic wedge modification to the left device (a thinning of the material directly under the entire first metatarsal with a 1/16-inch PPT [Langer Biomechanics Group, Deer Park, New York] backfill). His final F-Scan recording showed much higher pressures beneath the first metatarsophalangeal joint bilaterally and a much better center-of-force trajectory. His force-time curves showed a great improvement in symmetry and smoothness (Fig. 9). He did exceptionally well, with resolution of his knee pain, Achilles tendinitis, and plantar fasciitis within a few weeks.

## Case 3

A 20-year-old female Division I basketball player presented with pain on the ball of her right foot that had been bothering her for a long time. The patient had pain with callus development at the plantar aspect of the second and third metatarsal heads in the right foot. She had a very high-arched right foot, with a more pronated foot position on the left.

The patient had functional hallux limitus and a hypermobile first ray bilaterally. There was ankle joint equinus bilaterally, less than 5° of ankle joint range of motion, and no signs or symptoms of numbness or

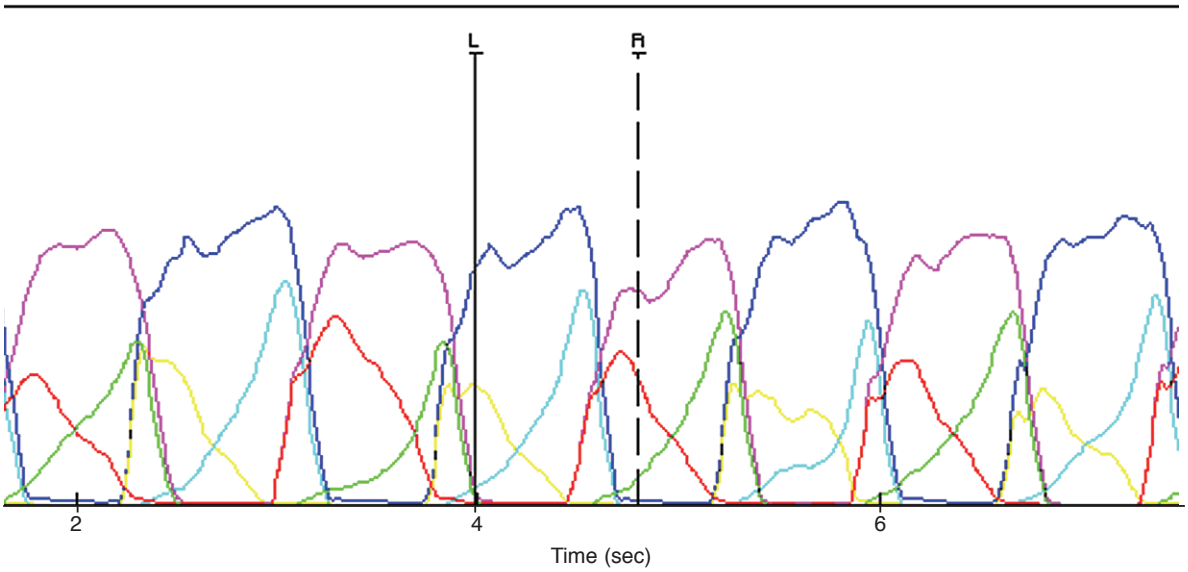


**Figure 8.** Case 2: Force-time curves of a male professional basketball player with uncomfortable orthoses. The blue curves represent the right foot; pink curves, the left foot; red (right) and yellow (left) curves, heel pressure; and green (right) and aqua (left) curves, forefoot pressure.

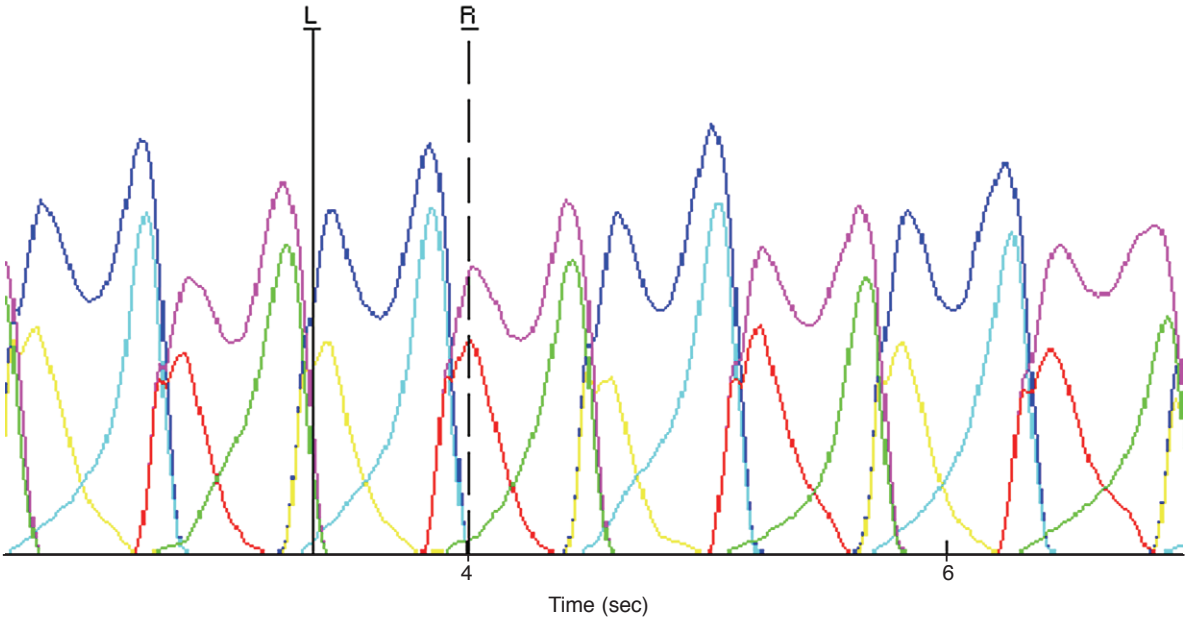


**Figure 9.** Case 2: Force-time curves of a male professional basketball player after modification of his permanent orthoses. The blue curves represent the right foot; pink curves, the left foot; red (right) and yellow (left) curves, heel pressure; and green (right) and aqua (left) curves, forefoot pressure.

shooting pain in the lesser toes bilaterally. The patient had a functional limb-length discrepancy with the left limb approximately 1/8 to 1/4 inch shorter than the right, but the discrepancy disappeared when the patient assumed the neutral calcaneal stance position. The primary working diagnosis was metatarsalgia beneath the second and third metatarsophalangeal joints in the right foot.

The patient's limb was taped using a modified low-Dye technique in which the first ray was more plantarflexed than usual, and this gave her relief. Manipulation of the ankle joint and proximal fibular head was performed,[20] and the patient had a 3° to 5° increase in ankle range of motion bilaterally. Because she had been helped so much by the low-Dye taping, she also underwent casting for custom foot orthoses.

The patient's initial F-Scan recording showed a lateral center-of-force trajectory, with very low pressures beneath the first metatarsophalangeal joint (Fig. 10). There were very high pressures beneath the fifth metatarsophalangeal joint as well as beneath the second and third metatarsophalangeal joints bilaterally. The patient also had no medial arch pressures bilaterally. Her initial force-time curves were asymmetrical bilaterally, with higher intensities on the right than the left and higher heel and forefoot pressures on the right than the left.

After F-Scan analysis, the patient was dispensed a final prescription of a 1/8-inch heel lift and a kinetic wedge modification on the left orthosis. In this final test, the recordings showed a more midline center-of-force trajectory bilaterally (Fig. 10). The pressures beneath the first metatarsophalangeal joint were increased bilaterally, whereas pressures beneath the fifth metatarsophalangeal joint decreased and, at least on the static images, those beneath the second and third metatarsophalangeal joint stayed largely the same. During the functional recordings, the overall timing of the peak pressures under the metatarsophalangeal joints was much shorter. The final force-time curves were much more symmetrical (Fig. 11). The patient reported that the orthoses were comfortable. At follow-up 2 weeks later, her symptoms had completely resolved.

## Case 4

A 19-year-old female Division I soccer player initially presented with low-back pain and bilateral knee pain. The symptoms had been present for 6 to 8 months, with no history of injury or trauma. The knee and back pain were exacerbated with running while playing soccer and during off-season conditioning. Swelling of the knee would occasionally occur with activity. She had undergone physical therapy and had tried two pairs of orthoses with no resolution of her symptoms.

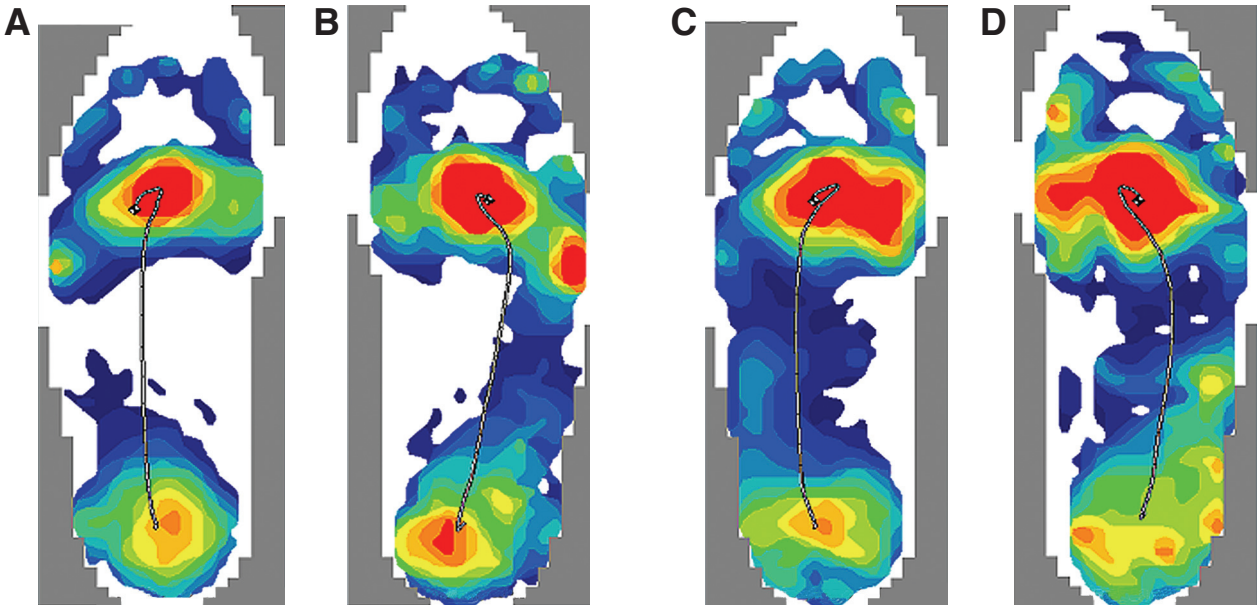


**Figure 10.** Case 3: In-shoe pressure recordings of a female Division I basketball player with metatarsalgia beneath the second and third metatarsophalangeal joints in the right foot. A and B, Left and right recordings before orthotic modification; C and D, left and right recordings after orthotic modification.

Magnetic resonance imaging of the knees and low back revealed no structural abnormalities.

Physical examination revealed functional hallux limitus bilaterally. When the first metatarsal head was not loaded, the first metatarsophalangeal joint range of motion was greater than 65°. Peroneus longus and tibialis posterior muscle strength was +5/5 bilaterally. A hypermobile first ray was noted bilaterally. There was a limb-length discrepancy, with the left leg 1/8 inch shorter than the right, in the relaxed calcaneal stance position that disappeared in the neutral calcaneal stance position.

Initially we noted that the center-of-pressure trajectory was lateral to the midline bilaterally, and the medial longitudinal arch pressures were absent in the static force-time curves. The force-time curves are poorly defined and very flattened bilaterally (Fig. 12). Bilateral first-ray cutouts were added, as well as a 1/8-inch heel lift in the left shoe. The final recordings showed that the center-of-pressure trajectory was now midline, and the medial arch pressures were increased. The force-time curves were much closer to symmetrical (Fig. 13). Within 1 week of beginning to wear the orthoses, her knee pain had resolved, and within 1 month her back pain had resolved.

## Conclusion

In-shoe pressure analysis is an extremely useful objective tool that aids in the evaluation and treatment of

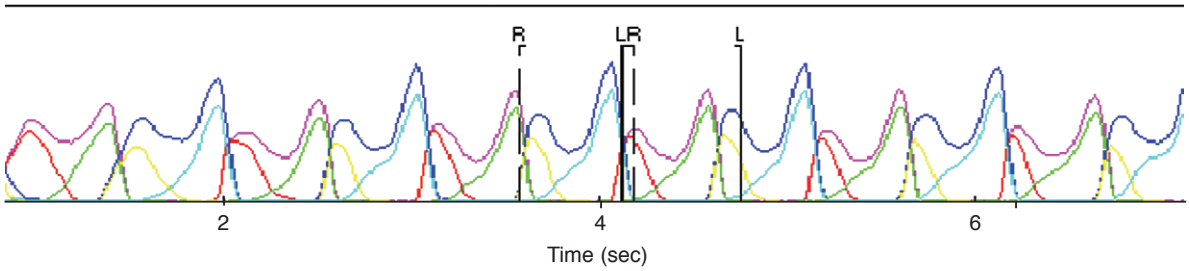


**Figure 11.** Case 3: Force-time curves of a female Division I basketball player with modified orthotic devices. The blue curves represent the right foot; pink curves, the left foot; red (right) and yellow (left) curves, heel pressure; and green (right) and aqua (left) curves, forefoot pressure.

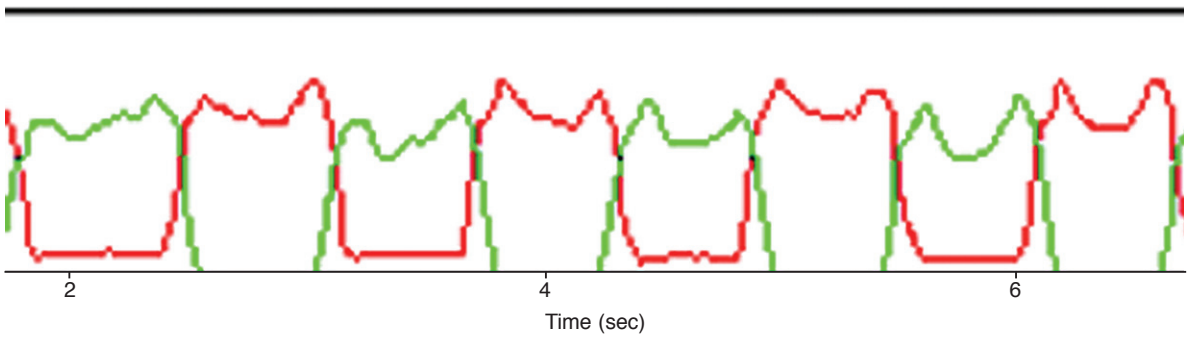


**Figure 12.** Case 4: Force-time curves of a female soccer player with no orthotic devices. The red curve represents the right foot; the green curve, the left foot.

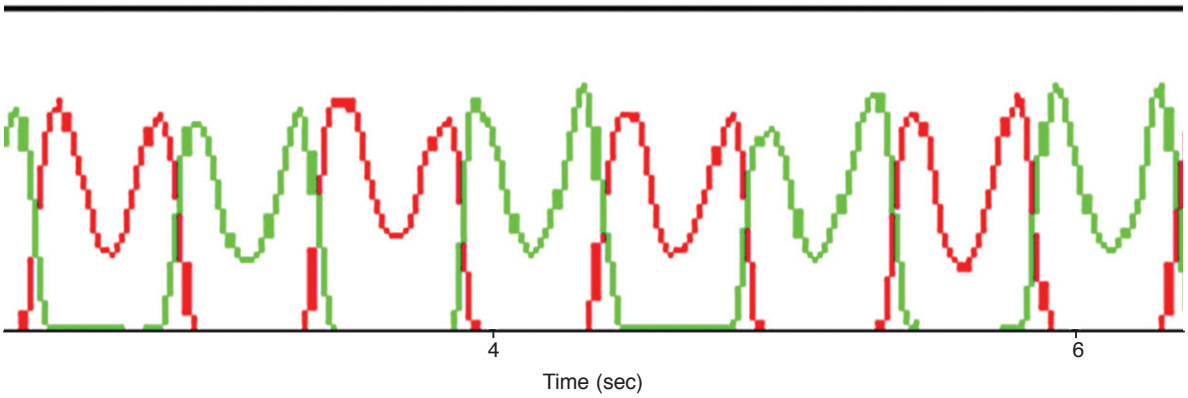


**Figure 13.** Case 4: Force-time curves of a female soccer player after F-Scan evaluation and with modified orthotic devices. The red curve represents the right foot; the green curve, the left foot.

athletic patients' gait pathologies. Awareness of the predominance of sagittal plane motion in the lower extremity can shed light on functional and structural problems in the feet and lower extremities that may cause a brief cessation of motion in the feet and ankles.

Synchronizing foot recordings for the evaluation of symmetry before and after modification of custom foot orthoses allows for objective recording of many important variables. Changes in force-time curves can indicate an improvement in foot function and overall orthosis comfort. The cases presented here give an indication of the variety of types of musculoskeletal pain that can be alleviated through simple modification in orthotic therapy as a result of evaluation using in-shoe pressure analysis.

**Financial Disclosures:** None reported.
**Conflict of Interest:** None reported.

## References

1. Oatis CA: "Goals of Gait Assessment," in *Gait Analysis*, ed by RL Craik, CA Oats, p 328, CV Mosby, St Louis, 1995.
2. Gage JR, Ounpuu S: Gait analysis in clinical practice. Semin Orthop **4:** 72, 1989.
3. Berenstein NA: "Biodynamics of Locomotion," in *Human Motor Actions: Berenstein Reassessed*, ed by HTA Whiting, p 171, North-Holland, Amsterdam, 1984.
4. Baumann W, Krabbe B, Farkas R: *The Application of In-Shoe Pressure Distribution Measurements in the Controlled Therapy of Diabetes Patients*, VTA Report No. 940, p 413, 1992. Available at: http://www.camatsystem.com/Yttryck/medicinbibliografi_1.htm. Accessed December 8, 2006.
5. Mueller MJ, Hastings M, Commean PK, et al: Forefoot structural predictors of plantar pressures during walking in people with diabetes and peripheral neuropathy. J Biomech **36:** 1009, 2003.
6. Dananberg HJ: Gait style as an etiology to chronic postural pain: part I. Functional hallux limitus. JAPMA **83:**

433, 1993.
7. Dananberg HJ: Gait style as an etiology to chronic postural pain: part II. Postural compensatory process. JAPMA **83:** 615, 1993.
8. Perry J: *Gait Analysis: Normal and Pathologic Function*, Slack, Thorofare, NJ, 1992.
9. Root M, Orien W, Weed J: *Abnormal and Normal Function of the Foot*, Vol 2, Clinical Biomechanics Corp, Los Angeles, 1977.
10. Wernick J, Volpe RG: "Lower Extremity Function and Normal Mechanics," in *Clinical Biomechanics of the Lower Extremities*, ed by R Valmassy, p 1, CV Mosby, St Louis, 1996.
11. Hall C, Nester CJ: Sagittal plane compensations for artificially induced limitation of the first metatarsophalangeal joint: a preliminary study. JAPMA **94:** 269, 2004.
12. Dananberg HJ: Functional hallux limitus and its relationship to gait efficiency. JAPMA **76:** 648, 1986.
13. DiNapoli DR, Dananberg HJ, Lawton M: "Hallux Limitus and Non-specific Bodily Trauma," in *Reconstructive Surgery of the Foot and Leg: Update '90*, ed by DR DiNapoli, The Podiatry Institute, Tucker, GA, 1990.
14. Dananberg HJ, Guiliano M: Chronic low-back pain and its response to custom-made foot orthoses. JAPMA **89:** 109, 1999.
15. Sarnow M, Veves A, Giurini J, et al: In-shoe foot pressure measurements in diabetic patients with at-risk feet and in healthy subjects. Diabetes Care **17:** 9, 1994.
16. Fuller EA: Center of pressure and its theoretical relationship to foot pathology. JAPMA **89:** 278, 1999.
17. Jong Paik N, Sik Im M: The path of center of pressure of the foot during walking. J Korean Acad Rehab Med **21:** 762, 1997.
18. Scherer PR, Sobiesk GA: The center of pressure index in the evaluation of foot orthoses in shoes. Clin Podiatr Med Surg **11:** 355, 1994.
19. Valmassy RL: "Computerized Gait Evaluation," in *Clinical Biomechanics of the Lower Extremities*, p 180, CV Mosby, St Louis, 1996.
20. Dananberg HJ: Manipulation of the ankle as a method of treatment for ankle and foot pain. JAPMA **94:** 395, 2004.